

Brachial Plexus Birth Palsy

Pre- and Post-Operative Upper Limb Motion Analysis – A Case Report



Kimberly Wesdock PT, MS, PCS^{1,2}; Christina Withers PT, PCS^{1,2}; Erin B. Rasnake MSPT¹;

George Masiello BSEET^{1,2}; Eugenio Monasterio MD^{1,2}; Chester Sharps MD^{1,2}

¹Children's Hospital - Richmond, Virginia; ²Virginia Commonwealth University - Richmond, Virginia

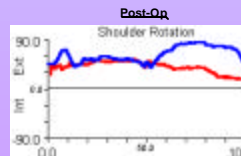
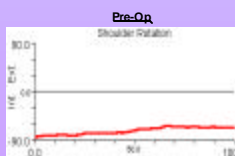
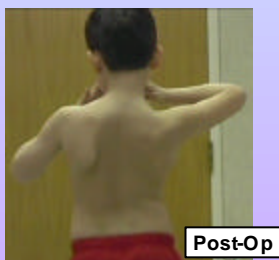
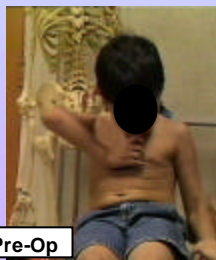
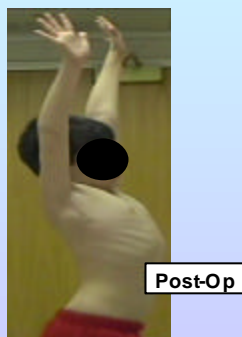
Background


When children with Brachial Plexus Birth Palsy (BPBP) plateau after physical therapy intervention, surgery may be an option. Due to the complexity of BPBP impairments, and the impact on participation and activities, surgical planning is very difficult and challenging. Upper Limb Motion Analysis, performed by pediatric physical therapist in a Motion Analysis Laboratory, assisted with surgical planning in this case, as well as outcome documentation after surgery and post-operative rehabilitation.

Case Description

- 5-year-old boy (BJ) with right Erb's Palsy
- No prior surgery; no physical therapy since the age of 2 years
- Impairments: Limited AROM/PROM of right shoulder flexion, external rotation, adduction and horizontal abduction
- Referred for Upper Limb Motion Analysis using Visual 3D
- Surgery performed (10 procedures)
- Post-op PT interventions
 - ✓ AROM / PROM exercises and mobilization
 - ✓ Electrical stimulation to anterior and middle deltoid
 - ✓ Ultrasound for shoulder adhesions
 - ✓ Kinesiotaping to activate scapular stabilizers and isolate glenohumeral motion during functional activities
- Post-op Upper Limb Motion Analysis performed using identical protocol 8 months after surgery
- Quantitative outcomes documented



Red is Involved Right Side; Blue is Normal Left Side



Kinematics with Pre-Op Surface Electromyography
During the task of hair combing using the right hand (requiring assist with the left because of limited external rotation of right shoulder)

Outcomes

Mallet Scores (Scale I – V)

	PRE-OP	POST-OP
Active Abduction	IV: 165° pre-op	IV: 170° post-op
External Rotation	I: Could not externally rotate to neutral (-75°)	III: Can now externally rotate to 20°
Hand to Nape of Neck	II: Could not do actively & reach nape	IV: Can now do easily
Hand to Low Back	III: Could reach S1 area	II: Now impossible to do; can only reach to side
Hand to Mouth	II: >90° sh abd to flex elbow	II: Does more easily

- Shoulder kinematics, AROM, and Mallet scores improved.
- EMGs showed reduced co-contractions post-op.
- PEDI scaled scores improved from 48.9 pre-op to 75.9 post-op.
- BJ noted improved ease of donning and doffing his shirt, and riding a 2-wheeled bicycle.

Discussion

Upper Limb Motion Analysis, performed by a pediatric physical therapist, provided a standardized and objective way to quantify specific improvements after treatment interventions in a child with BPBP. Longitudinal evaluations are planned to document residual impairments and function over time.

